

Cyberknife Radiotherapy for Vestibular Schwannoma

Gordon T. Sakamoto, MD^{a,*}, Nikolas Blevins, MD^b, Iris C. Gibbs, MD^c

KEYWORDS

- Stereotactic radiosurgery • Vestibular schwannomas
- Cyberknife • Fractionation

Most vestibular schwannomas are benign and slow-growing. Based on that fact, conservative management with serial imaging is a viable alternative.¹ For patients who undergo treatment because of tumor growth, progressive symptoms, or personal preference, options include serial observation, microsurgical resection, fractionated stereotactic radiotherapy, and stereotactic radiosurgery. There remains some debate as to how best to manage these tumors. Historically, vestibular schwannomas have been treated with microsurgical resection. Loss of hearing and facial nerve injury, however, are not uncommon microsurgical complications. Fractionated radiotherapy was used initially as an adjunct to microsurgery in patients who had undergone subtotal resection, and demonstrated the overall effectiveness of radiation for treating vestibular schwannomas.² Over the last few decades, stereotactic radiosurgery has emerged as a safe and effective treatment modality for vestibular schwannomas.^{3–11} Owing mainly to the unknown risks of secondary tumors and possible late effects of stereotactic radiation, stereotactic radiosurgery initially was reserved for patients who were poor microsurgical candidates, or as an adjuvant treatment for residual or recurrent tumor. The long-term data of stereotactic radiosurgery now support the efficacy of this treatment modality. Historical reviews also suggest that secondary tumors are rare after radiosurgery.¹² For these reasons, stereotactic radiosurgery has emerged as the preferred treatment modality, as it offers lower morbidity than surgical resection and excellent long-term tumor control.^{4,7,13,14}

Traditionally, stereotactic radiosurgery required the use of rigid immobilization using a stereotactic frame to achieve treatment precision and accuracy. The Cyberknife (Accuray, Incorporated, Sunnyvale, California), which was introduced in 1994, does

^a Department of Neurosurgery, Stanford University School of Medicine, Stanford, CA, USA

^b Department of Otolaryngology, Stanford University School of Medicine, Stanford, CA, USA

^c Radiation Oncology, Stanford University School of Medicine, Stanford, CA, USA

* Corresponding author.

E-mail address: gtsaka@yahoo.com (G.T. Sakamoto).

not require the use of rigid immobilization. Although the Cyberknife does not require the use of a stereotactic frame, its accuracy is comparable to frame-based radiosurgery.¹⁵ Additionally, because the Cyberknife does not employ a rigid frame, it is practical to fractionate or stage Cyberknife treatments over several days to decrease the risk of radiation injury to adjacent critical structures, such as the brainstem or cochlea.

THE CYBERKNIFE

Stereotactic radiosurgery is a radiation technique that can deliver therapeutic doses of radiation with submillimeter accuracy and a rapid dose fall-off at the periphery of the target. Leksell first conceived the concept of radiosurgery in the 1950s¹⁶ and created the Gamma Knife, which used multiple cobalt sources to treat a target as defined on pretreatment imaging data. Since then, stereotactic radiosurgery has advanced with technologic improvements in computing and imaging. For three decades, stereotactic targeting that required rigid skeletal fixation to provide registration between pretreatment plan and target anatomy was at the center of all radiosurgical systems, especially the gold standard Gamma Knife. In the 1990s, John Adler, however, created the CyberKnife, a robotic frameless radiotherapy system that uses real-time acquisition of the patient's bony anatomy for image-guidance.¹⁷

The Cyberknife is a frameless, image-guided, robotic radiotherapy system. Therapeutic radiation is emitted from a compact 6 MV linear accelerator mounted on a robotic arm (**Fig. 1**). The arm is programmed to move the linear accelerator sequentially through a predetermined series of locations. At each location, radiation is delivered to the target volume. The trajectory and dose delivered at each location are calculated so that their cumulative effect optimizes the coverage of the target volume while minimizing the exposure of adjacent tissues. The Cyberknife can generate beams from more than 1200 directions. This allows for nonisocentric radiation planning that can optimize dose conformality and homogeneity. The need for rigid fixation is circumvented by real-time image guidance. For intracranial targets, patients are relatively immobilized with an Aquaplast mask (WFR/Aquaplast Company, Wyckoff, New Jersey) (**Fig. 2**). Flat-panel radiograph detectors are mounted on either side of

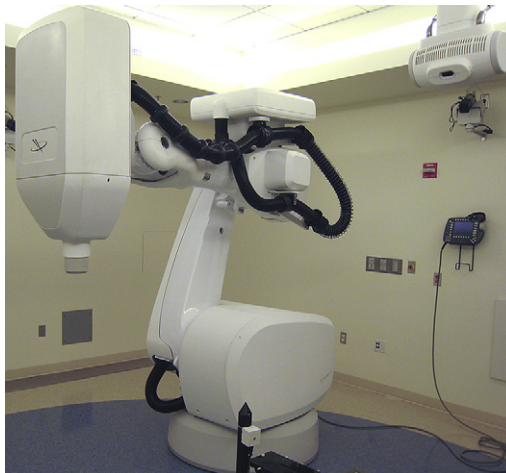

Fig. 1. The Cyberknife is a linear accelerator mounted on a robotic arm that employs image guidance to eliminate the need for a stereotactic frame.




Fig. 2. A custom-fit Aquaplast mask is shown attached to the treatment table.

the treatment table and obtain orthogonal radiograph images in real time during the treatment. These images are referenced to digitally reconstructed radiographs (DRRs) that are created from CT datasets obtained during treatment planning. The patient's position is verified by his or her own bony anatomy. The image guidance software compares differences in three translational and three rotational axes, and adjustments are made with the treatment couch and robotic arm. This process is updated throughout the radiotherapy treatment to maintain accuracy.¹⁵

RADIOSURGERY FOR VESTIBULAR SCHWANNOMA

Leksell pioneered the use of stereotactic radiosurgery for treating vestibular schwannomas in 1969. He later published his initial experience with vestibular schwannoma radiosurgery using the Gamma Knife in 1971.¹⁸ Since then, stereotactic radiosurgery has proven to be a safe and effective treatment option for managing vestibular schwannomas. Numerous radiosurgical series exist in the literature detailing excellent tumor control rates ranging from 92% to 100% in the first several years after treatment using the Gamma Knife.^{4,7-9,13,19,20} Additionally, many studies have confirmed excellent longer-term control rates at 5 and 10 years after treatment.^{7,13,19,20}

Over the last decade, attention has been directed to improving the hearing preservation rates following radiosurgery and reducing other treatment-related morbidities. Initial radiosurgery series reported hearing preservation rates that ranged from 51% to 60%⁷⁻⁹ with significant rates of facial weakness and numbness.⁷ Improvements in conformal radiation treatment delivery and use of lower marginal prescription doses, however, have improved steadily the 3- to 5-year hearing preservation rate to between 68% and 77% while also reducing rates of facial weakness and numbness.^{4,10,11,13,19} Despite improved Gamma Knife radiosurgical techniques and lower marginal doses, a recent report has shown a somewhat disappointing 10-year actuarial hearing preservation rate of 44.5%, with hearing loss developing as much as 6 years after treatment.¹³

Studies have demonstrated that the total radiation dose to the cochlea is a critical factor in hearing preservation.^{21,22} Fractionation of the total dose, or staging, however, also may play a fundamental role. Staging radiation treatments long has been proposed as a means to reduce the risk of injury to adjacent critical structures such as the brainstem, cranial nerves, and cochlea.^{23–28} Fractionation of the prescribed dose takes advantage of radiobiologic principles to reduce toxicity and maintain tumor control.^{28,29} The authors' initial experience with staged frame-based radiotherapy using 21 Gy in three fractions and a 12-hour interfraction interval showed a 77% hearing preservation rate at 2 years.²⁶ Experience, however, with dose staging using an interfraction interval of 24 hours was limited, as frame-based radiotherapy techniques would require that the patient remain hospitalized while wearing a stereotactic frame continuously over the course of several days.

Based on the proof of principle established in the authors' staged framed-based study and the introduction of the Cyberknife, it became possible to accurately deliver highly conformal radiation to vestibular schwannomas and fractionate the prescribed dose in an attempt to spare the adjacent brainstem and cochlea. The treatment of the first vestibular schwannoma with the Cyberknife occurred in 1999. Since then, over 350 vestibular schwannomas have been treated at Stanford using the Cyberknife employing a standard 3-day staging protocol.

PATIENT SELECTION

A team that consists of a neurosurgeon or otolaryngologist and a radiation oncologist experienced in the treatment of vestibular schwannomas evaluates all patients treated with Cyberknife radiosurgery. All treatment options, including conservative management and microsurgical resection, are considered by the team.

Cyberknife radiosurgery is offered to patients with unilateral or bilateral vestibular schwannomas that are less than 3 cm in diameter within the cerebellopontine angle. The Cyberknife also can be used to treat residual vestibular schwannomas after a planned subtotal microsurgical resection or those that recur despite apparent gross total removal. Patients demonstrating tumor growth following radiotherapy or radiosurgical treatment also can be considered for retreatment. Retreatment is considered no sooner than 1 year after radiotherapy treatment. Patients who are not microsurgical candidates because of advanced age or other risk factors or patients who do not wish to undergo microsurgical treatment may be candidates for Cyberknife treatment. Additionally, patients who have neurofibromatosis type II (NF2) are also candidates for Cyberknife treatment, although as a group this population does not seem to respond as well to treatment as do patients who have sporadic unilateral tumors.³⁰

PRETREATMENT EVALUATION

A pretreatment gadolinium-enhanced MRI is obtained in all patients within the 3 months before treatment. The tumor is measured in three orthogonal dimensions. The intracanalicular portion (if any) is included in the maximal transverse diameter when calculating measurements.

Pretreatment audiograms are obtained within 3 months before treatment to document baseline hearing unless anacusis has been documented previously. The word recognition score and pure tone average in decibels are recorded. Hearing is graded on the Gardner-Robertson (G-R) scale.³¹

Clinical evaluation of the patient's neurologic status is performed before treatment. Special attention is given to the fifth, seventh, and eighth cranial nerve examination, and any baseline deficits or palsies are noted. Trigeminal nerve function is graded

on a semiquantitative scale as normal sensation, decreased sensation, or no sensation. Facial nerve function is graded on the House-Brackmann (H-B) scale.³²

TREATMENT PLANNING AND RADIOSURGERY DELIVERY

All patients initially are fitted with a custom made Aquaplast mask and thin foam head-rest to ensure consistent positioning from the acquisition of the imaging studies through the radiotherapy treatment. While in the mask, a thin slice (1.25 mm) high-resolution (CT) scan of the entire head is obtained with a GE Light Speed 8i Scanner (Milwaukee, Wisconsin) after the intravenous administration of 125 mL of Omnipaque contrast (iohexol, 350 mg I/mL; Nycomed, Incorporated, Princeton, New Jersey). The acquired images then are transferred to the Cyberknife treatment planning workstation. When the tumor is identified readily on the CT, with morphology and dimensions consistent with those of the pretreatment MRI, target planning can be done using CT imaging alone. In the authors' experience, nearly all vestibular schwannomas can be delineated accurately with the high-resolution, thin-slice contrast CT imaging alone.

In the rare instance that CT imaging is not optimal, or if a patient cannot tolerate iodinated contrast used during acquisition of the CT, a thin slice (2 mm) gadolinium-enhanced T1 weighted MRI is obtained. This MRI then is fused to the CT using the Cyberknife treatment planning software to create a composite image for tumor localization. This method helps define the extent of smaller tumors and can help further define intracanalicular lesions. Additionally, most digital imaging and communication in medicine (DICOM) format imaging studies can be imported and fused to the standard CT image. The high-resolution, thin-slice CT scan is always necessary to provide the skeletal anatomy used for real-time patient tracking during treatment.

The treating surgeon then manually defines the tumor volumes and critical structures on the axial images (**Fig. 3**). Although the axial images normally are used for treatment planning, it is possible to delineate structures on the either the coronal or sagittal images. It is usually necessary to adjust the windows and levels of the treatment planning CT dataset to optimize clarity of the bone of the internal auditory canal to improve definition of the tumor margins. In addition, the cochlea is defined better

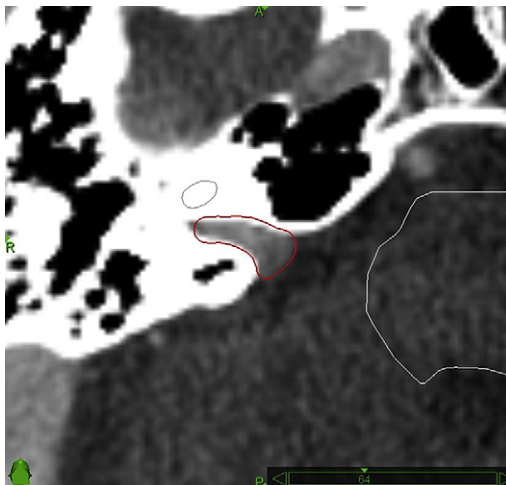


Fig. 3. Right-sided intracanalicular vestibular schwannoma outlined as the radiotherapy target with the cochlea and brainstem outline as critical structures.

when CT window levels are set for bone visualization. It should be emphasized that target definition can be a complex process in recurrent or postoperative lesions, and in rare circumstances, it may require the input of an experienced neuroradiologist.

Once the tumor and critical structures are delineated, nonisocentric, inverse planning using the Cyberknife treatment planning software helps to achieve a highly conformal radiotherapy dose that minimizes dose to the adjacent critical structures (**Fig. 4**). Nonisocentric planning allows the beams of radiation to originate from many different points in space to create an even dose distribution to nonspherical lesions. This differs from isocentric planning, in which one or more spherical dose distributions are used to cover the tumor shape. The Cyberknife can do both isocentric and nonisocentric planning; however, for irregularly shaped tumors, such as vestibular schwannomas, nonisocentric planning is used. Inverse planning allows the physician to input specific treatment criteria and dose tolerances. Then the treatment planning software selects the beams and beam weights to compute a radiotherapy plan that meets the treatment criteria. This is in contrast to forward planning, in which the user manually selects the beams and beam weights to be used. The treatment plan is evaluated by the treating surgeon and the radiation oncologist. The treatment plan is evaluated and selected based on an analysis of the volumetric dose and the dose–volume histograms of the target volume and the adjacent critical structures. The number of paths and beams used for each patient varies and is determined by the selected individual treatment plan.

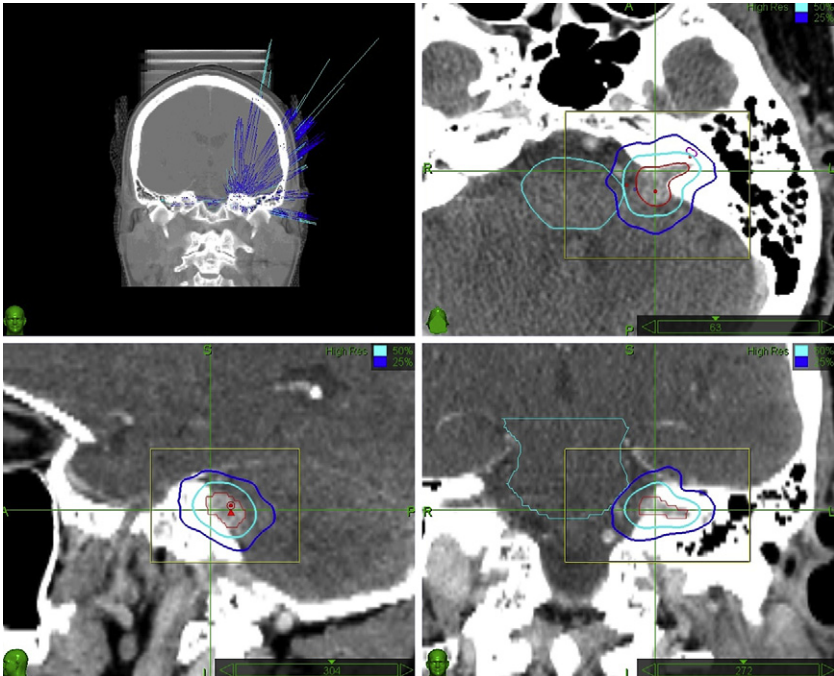


Fig. 4. Treatment plan for a left-sided vestibular schwannoma involving the left internal auditory canal and cerebellopontine angle cistern treated with 18 Gy delivered in three equal fractions. The dose distribution is contoured to minimize irradiation of the cochlea and brainstem. The tumor volume is depicted as well as the 50% and 25% isodose lines in three planes.

Once the treatment plan has been created and approved by the treating physicians, the patient is brought back and placed supine on the treatment couch. The Aquaplast mask then is put on the patient and affixed to the treatment couch to ensure consistent positioning throughout the treatment. The treatment couch is adjusted as necessary to align the patient with the previously generated DRRs. Once the patient is aligned properly, treatment begins. Each fraction lasts between 30 and 45 minutes. Following each radiotherapy fraction, patients are treated with an oral dose of 4 mg of dexamethasone for prophylaxis of acute radiation toxicity.

POST-TREATMENT FOLLOW-UP

For the first 2 years after radiosurgery, a thin slice (2 to 3 mm) gadolinium-enhanced MRI is obtained every 6 months. MR images are obtained annually after the first 2 years. Tumor size is measured in three orthogonal dimensions on each follow-up scan and compared with the pretreatment measurements. Tumors then are categorized as stable, smaller, or larger than the pretreatment dimensions.

For the first 2 years after radiosurgery, audiograms are obtained every 6 months. After the first 2 years, pure-tone audiograms and word recognition scores are obtained annually or if a hearing change is reported. Whenever possible, patients obtain audiograms at the same center to minimize discrepancies related to technique. Directed neurologic examination and testing of the fifth, seventh, and eighth cranial nerves is performed every 6 months for the first 2 years. Neurologic testing occurs annually thereafter.

STANFORD UNIVERSITY CYBERKNIFE EXPERIENCE

Between 1999 and 2001, 61 patients who had unilateral vestibular schwannomas underwent tri-fractionated Cyberknife radiosurgery at Stanford University using the protocol outlined previously.³³ Mean patient age was 54 years (range 27 to 79 years), and 31 (51%) of the vestibular schwannomas were located on the right side, while 30 were located on the left side. Eight patients had a prior microsurgical resection on the treated side. These eight patients either demonstrated residual tumor on postoperative scans or a new recurrence on follow-up scans. None of the patients in this series carried the diagnosis of NF2.

The mean pretreatment maximal tumor dimension was 18.5 mm (range 5 to 32 mm). The initial treatment dose was 21 Gy over 3 days for the first 14 patients. This dose was based on the authors' prior experience with frame-based radiosurgery and selected based on the radiobiological equivalence to a single 14 Gy dose.²⁶ Based on excellent tumor control and evidence that a reduced dose could maintain tumor control rates while improving hearing preservation,^{10,34} the dose was lowered to 18 Gy delivered in three equal fractions delivered on consecutive days (18 Gy in three fractions is approximately equal to 11.5 Gy in one single treatment session). The treatment dose was prescribed to the 70% to 80% isodose contour line at the periphery of the tumor. In every case, the total dose was given in equal fractions over the course of 3 consecutive days. After each fraction was delivered, 4 mg of dexamethasone was administered orally.

All patients received an MRI, audiogram, and clinical follow up every 6 months for the first 2 years. After the first 2 years, the patients were followed with annual MRIs, audiograms, and clinic visits. Mean clinical and radiological follow-up for this series was 48 months (range 36 to 62) months.

Radiologically, 29 of 61 tumors decreased in size, and 31 tumors had no change in size, producing a tumor control rate of 98% (Fig. 5). The loss of central enhancement

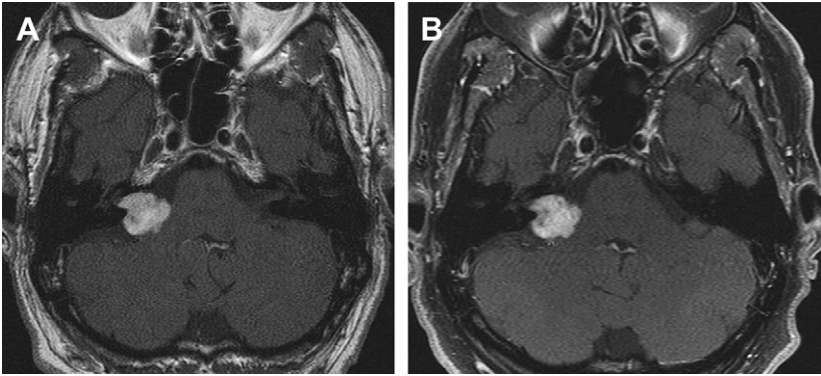


Fig. 5. (A) Axial T1 weighted gadolinium-enhanced MRI of a right-sided vestibular schwannoma before Cyberknife radiosurgery. (B) Follow-up axial T1 weighted gadolinium-enhanced MRI taken 6 years after Cyberknife radiosurgery demonstrating no evidence of tumor progression.

within the tumor was noted routinely between 6 and 12 months after radiosurgery. One patient was noted to have an increase in tumor size 4 years after treatment. The tumor dimensions all increased by 50%. At 3 years after treatment, the tumor was minimally larger than pretreatment dimensions. The patient did not develop new neurologic symptoms with tumor growth. This patient ultimately underwent a microsurgical resection.

Of the 61 patients in this series, 13 patients had no hearing (G-R grade 5) before treatment. These patients were not followed with serial audiograms. The remaining 48 patients all had some degree of hearing (G-R grade 1 to 3) before treatment. Of the 48 patients with hearing before treatment, 43 (90%) retained hearing (G-R grade 1 to 3) at last follow-up. Thirty-five patients had G-R grade 1 to 2 hearing before treatment, and 26 (74%) of these patients maintained this level of hearing at last follow-up. Two patients' hearing actually improved after treatment with the Cyberknife. One patient's hearing improved from a G-R grade 2 to a grade 1, and the other patient improved from a G-R grade 3 to a grade 1.

No patient treated with the Cyberknife developed a new facial weakness. One patient had a H-B grade 3 facial weakness before treatment that remained stable after radiosurgery. Two patients had transient facial twitching within the first 12 months after radiosurgery. One patient's twitching resolved in 3 months, and the other resolved in 5 months.

Trigeminal function was assessed at each follow up using a semiquantitative scale. Trigeminal dysfunction usually is seen in association with larger tumors. Smaller tumors and intracanalicular tumors are relatively distant from the trigeminal nerve. In this series, no patients experienced trigeminal nerve deficits after radiosurgery, regardless of tumor size.

One patient who had undergone previous microsurgical resection developed symptoms from brainstem edema within the first 12 months after radiotherapy. Five months after radiotherapy, the patient experienced left lower extremity sensory loss. Imaging demonstrated a T2 signal change along the lateral brainstem. The patient's symptoms resolved over a period of 3 months and the imaging abnormalities fully resolved on subsequent studies.

In summary, this series demonstrated excellent short tumor control rates with good hearing preservation and few cranial nerve deficits. A recent Gamma Knife study

suggests that cranial nerve deficits after radiosurgery can occur up to 5 years after treatment.³⁵ Additionally, another recent Gamma Knife study reported that the hearing preservation rate continues to decline even 6 years after treatment.¹³ Therefore, additional studies with longer follow-up after Cyberknife radiosurgery are underway to determine if fractionation of the radiotherapy dose can improve upon previously reported Gamma Knife results.

SUMMARY

Vestibular schwannomas are benign tumors, which are amenable to both microsurgical and radiotherapy or radiosurgical treatments. For patients with small- to medium-sized tumors, who are poor microsurgical candidates or who do not wish to undertake the risks associated with microsurgical resection, Cyberknife stereotactic radiotherapy offers excellent tumor control and hearing preservation with minimal facial and trigeminal morbidity. Further studies with longer follow-up are needed and underway. Based on the Stanford University experience, fractionated Cyberknife radiotherapy appears to be a safe and effective primary treatment for vestibular schwannomas.

REFERENCES

1. Smouha EE, Yoo M, Mohr K, et al. Conservative management of acoustic neuroma: a meta-analysis and proposed treatment algorithm. *Laryngoscope* 2005;115:450–4.
2. Wallner KE, Sheline GE, Pitts LH, et al. Efficacy of irradiation for incompletely excised acoustic neurilemmomas. *J Neurosurg* 1987;67:858–63.
3. Bertalanffy A, Dietrich W, Aichholzer M, et al. Gamma knife radiosurgery of acoustic neurinomas. *Acta Neurochir (Wien)* 2001;143:689–95.
4. Flickinger JC, Kondziolka D, Niranjan A, et al. Results of acoustic neuroma radiosurgery: an analysis of 5 years' experience using current methods. *J Neurosurg* 2001;94:1–6.
5. Flickinger JC, Lunsford LD, Coffey RJ, et al. Radiosurgery of acoustic neurinomas. *Cancer* 1991;67:345–53.
6. Flickinger JC, Lunsford LD, Linskey ME, et al. Gamma knife radiosurgery for acoustic tumors: multivariate analysis of four-year results. *Radiother Oncol* 1993;27:91–8.
7. Kondziolka D, Lunsford LD, McLaughlin MR, et al. Long-term outcomes after radiosurgery for acoustic neuromas. *N Engl J Med* 1998;339:1426–33.
8. Linskey ME, Lunsford LD, Flickinger JC. Radiosurgery for acoustic neurinomas: early experience. *Neurosurgery* 1990;26:736–44 [discussion: 44–5].
9. Lunsford LD, Linskey ME. Stereotactic radiosurgery in the treatment of patients with acoustic tumors. *Otolaryngol Clin North Am* 1992;25:471–91.
10. Niranjan A, Lunsford LD, Flickinger JC, et al. Dose reduction improves hearing preservation rates after intracanalicular acoustic tumor radiosurgery. *Neurosurgery* 1999;45:753–62 [discussion: 62–5].
11. Spiegelmann R, Gofman J, Alezra D, et al. Radiosurgery for acoustic neurinomas (vestibular schwannomas). *Isr Med Assoc J* 1999;1:8–13.
12. Rowe J, Grainger A, Walton L, et al. Risk of malignancy after gamma knife stereotactic radiosurgery. *Neurosurgery* 2007;60:60–5 [discussion: 65–6].
13. Chopra R, Kondziolka D, Niranjan A, et al. Long-term follow-up of acoustic schwannoma radiosurgery with marginal tumor doses of 12 to 13 Gy. *Int J Radiat Oncol Biol Phys* 2007;68:845–51.

14. Pollock BE, Lunsford LD, Kondziolka D, et al. Outcome analysis of acoustic neuroma management: a comparison of microsurgery and stereotactic radiosurgery. *Neurosurgery* 1995;36:215–24 [discussion: 24–9].
15. Chang SD, Main W, Martin DP, et al. An analysis of the accuracy of the Cyberknife: a robotic frameless stereotactic radiosurgical system. *Neurosurgery* 2003;52:140–6 [discussion: 46–7].
16. Leksell L. The stereotaxic method and radiosurgery of the brain. *Acta Chir Scand* 1951;102:316–9.
17. Adler JR Jr, Chang SD, Murphy MJ, et al. The Cyberknife: a frameless robotic system for radiosurgery. *Stereotact Funct Neurosurg* 1997;69:124–8.
18. Leksell L. A note on the treatment of acoustic tumours. *Acta Chir Scand* 1971;137:763–5.
19. Hasegawa T, Fujitani S, Katsumata S, et al. Stereotactic radiosurgery for vestibular schwannomas: analysis of 317 patients followed more than 5 years. *Neurosurgery* 2005;57:257–65 [discussion: 57–5].
20. Hasegawa T, Kida Y, Kobayashi T, et al. Long-term outcomes in patients with vestibular schwannomas treated using gamma knife surgery: 10-year follow up. *J Neurosurg* 2005;102:10–6.
21. Massager N, Nissim O, Delbrouck C, et al. Irradiation of cochlear structures during vestibular schwannoma radiosurgery and associated hearing outcome. *J Neurosurg* 2007;107:733–9.
22. Thomas C, Di Maio S, Ma R, et al. Hearing preservation following fractionated stereotactic radiotherapy for vestibular schwannomas: prognostic implications of cochlear dose. *J Neurosurg* 2007;107:917–26.
23. Flickinger JC. An integrated logistic formula for prediction of complications from radiosurgery. *Int J Radiat Oncol Biol Phys* 1989;17:879–85.
24. Lederman G, Lowry J, Wertheim S, et al. Acoustic neuroma: potential benefits of fractionated stereotactic radiosurgery. *Stereotact Funct Neurosurg* 1997;69:175–82.
25. Lo YC, Ling CC, Larson DA. The effect of setup uncertainties on the radiobiological advantage of fractionation in stereotaxic radiotherapy. *Int J Radiat Oncol Biol Phys* 1996;34:1113–9.
26. Poen JC, Golby AJ, Forster KM, et al. Fractionated stereotactic radiosurgery and preservation of hearing in patients with vestibular schwannoma: a preliminary report. *Neurosurgery* 1999;45:1299–305 [discussion: 305–07].
27. Varlotto JM, Shrieve DC, Alexander E 3rd, et al. Fractionated stereotactic radiotherapy for the treatment of acoustic neuromas: preliminary results. *Int J Radiat Oncol Biol Phys* 1996;36:141–5.
28. Williams JA. Fractionated stereotactic radiotherapy for acoustic neuromas. *Int J Radiat Oncol Biol Phys* 2002;54:500–4.
29. Andrews DW, Suarez O, Goldman HW, et al. Stereotactic radiosurgery and fractionated stereotactic radiotherapy for the treatment of acoustic schwannomas: comparative observations of 125 patients treated at one institution. *Int J Radiat Oncol Biol Phys* 2001;50:1265–78.
30. Mathieu D, Kondziolka D, Flickinger JC, et al. Stereotactic radiosurgery for vestibular schwannomas in patients with neurofibromatosis type 2: an analysis of tumor control, complications, and hearing preservation rates. *Neurosurgery* 2007;60:460–8 [discussion: 68–70].
31. Gardner G, Robertson JH. Hearing preservation in unilateral acoustic neuroma surgery. *Ann Otol Rhinol Laryngol* 1988;97:55–66.

32. House JW, Brackmann DE. Facial nerve grading system. *Otolaryngol Head Neck Surg* 1985;93:146–7.
33. Chang SD, Gibbs IC, Sakamoto GT, et al. Staged stereotactic irradiation for acoustic neuroma. *Neurosurgery* 2005;56:1254–61 [discussion: 61–3].
34. Spiegelmann R, Lidar Z, Gofman J, et al. Linear accelerator radiosurgery for vestibular schwannoma. *J Neurosurg* 2001;94:7–13.
35. Lunsford LD, Niranjan A, Flickinger JC, et al. Radiosurgery of vestibular schwannomas: summary of experience in 829 cases. *J Neurosurg* 2005;102(Suppl): 195–9.